

The Journal of
Thoracic and Cardiovascular Surgery

**Feasibility of preservation of subvalvular apparatus in mitral valve replacement
with the On-X mechanical valve**

Hiroshi Tanaka, Teruo Yamshita, Kenji Okada, Keitaro Nakagiri, Yujiro Kawanishi
and Yutaka Okita

J Thorac Cardiovasc Surg 2006;132:1470-1471

DOI: 10.1016/j.jtcvs.2006.08.030

The online version of this article, along with updated information and services, is
located on the World Wide Web at:

<http://jtcs.ctsnetjournals.org/cgi/content/full/132/6/1470>

The Journal of Thoracic and Cardiovascular Surgery is the official publication of the American Association for Thoracic Surgery and the Western Thoracic Surgical Association. Copyright © 2006 American Association for Thoracic Surgery

Feasibility of preservation of subvalvular apparatus in mitral valve replacement with the On-X mechanical valve

Hiroshi Tanaka, MD, Teruo Yamshita, MD, Kenji Okada, MD, Keitaro Nakagiri, MD, Yujiro Kawanishi, MD, and Yutaka Okita, MD, Kobe, Japan

Preserving subvalvular apparatus in mitral valve replacement brings a significant long-term advantage by preserving left ventricular function. The possibility of prosthetic valve entrapment of the retained subvalvular apparatus, left

ventricular outflow tract obstruction, and implantation of a smaller-sized prosthesis has been of major concern to investigators advocating this procedure. Recently introduced, the On-X mechanical valve (Medical Carbon Research Institute, Austin, Tex) has the advantage of reduced anticoagulation and a specific structure of leaflet flare for protection from retained subvalvular apparatus and pannus encroachment. We operated on 6 patients requiring mitral valve replacements using the On-X mechanical mitral valve and obtained good results without complications associated with this procedure.

Clinical Summary

From October 2005 to March 2006, 6 patients underwent mitral valve replacement for mitral valve stenosis using the On-X mitral valves with the techniques of preserving mitral papillary muscle continuity.

From Kobe University Hospital, Department of Cardiovascular, Thoracic, and Pediatric Surgery, Kobe, Japan.

Received for publication July 15, 2006; accepted for publication Aug 8, 2006.

Address for reprints: Hiroshi Tanaka, MD, Kobe University Hospital, Department of Cardiovascular, Thoracic, and Pediatric Surgery, 7-5-2, Kusunoki-cho, Chuo-ku, Kobe, Japan (E-mail: hirot@ams.odn.ne.jp).

J Thorac Cardiovasc Surg 2006;132:1470-4

0022-5223/\$32.00

Copyright © 2006 by The American Association for Thoracic Surgery

doi:10.1016/j.jtcvs.2006.08.030

TABLE 1. Techniques for preserving subvalvular apparatus and pre- and postoperative electrocardiography data

Case	Technique for preserving mitral-papillary muscle continuity	Preop		Postop		
		LVDd/Ds (mm)	EF (%)	LVDd/Ds (mm)	EF (%)	LVOT PG (mm Hg)
1	Artificial chordae ×4	43/30	70	42/36	64	5.4
2	PML preserved	38/23	64	38/28	71	6.7
3	Artificial chordae ×4	49/37	40	48/36	50	11.4
4	PML and lateral part of AML preserved; artificial chordae ×1	53/35	48	55/35	50	16.6
5	Artificial chordae ×4	47/28	64	48/25	63	12.9
6	PML preserved; artificial chordae ×2	53/40	42	55/40	45	4.8

LVDd, Left ventricular dimension diastole; Ds, dimension systole; EF, ejection fraction; LVOT PG, pressure gradient across the left ventricular outflow tract; PML, posterior mitral leaflet; AML, anterior mitral leaflet.

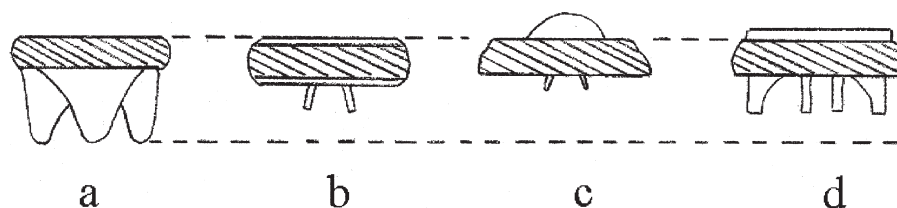


Figure 1. Comparing the profiles of prosthetic valves. a, Stentless bioprosthesis; b, Carbomedics standard valve; c, St Jude Medical Standard valve; d, the On-X valve.

Methods

After cardiopulmonary bypass is established, the aorta is clamped and cardioplegic arrest is obtained. The left atrium is opened from the right side after dissecting the groove. A Cosgrove retractor is inserted, and the mitral valve is examined. Basically, autologous subvalvular apparatus is meant to be preserved. However, in case of severe calcified subvalvular apparatus that cannot be preserved, we reconstruct the chordae tendineae with polytetrafluoroethylene sutures (Gore-Tex suture; W. L. Gore & Associates, Inc, Flagstaff, Ariz) as artificial chordae. If the patient's left ventricle is so small that the retained subvalvular apparatus may cause left ventricular outflow obstruction, preserving the continuity on the anterior mitral leaflet side is abandoned. The On-X valve is implanted with 2-0 Ethibond everting mattress sutures (Ethicon, Inc, Somerville, NJ) in the antianatomic position.

Results

No patients died in the hospital or during the follow-up period. Echocardiography was performed 1 month after the operation. The preservation techniques and preoperative and postoperative echocardiographic data are shown in Table 1. Left ventricular function was maintained or improved in all cases. No instances of prosthetic valve dysfunction and no significant pressure gradients across the left ventricular outflow tract were recorded.

Comments

Chordal preservation in mitral valve replacement has been widely accepted because of the advantage of preserving left ventricular function and decreasing the risk for ventricular rupture in mitral valve replacement.¹ This technique should incorporate several principles²: (1) The procedure must not cause left ventricular outflow obstruction. (2) Retained subvalvular structures should not interfere with the prosthetic valve mechanism. (3) Sufficient tissue should be resected to allow for implantation of a suitably sized valve.

Currently, various kinds of prosthetic valves are available in mitral valve surgery. The St Jude Medical mitral valve (St Jude Medical, Inc, St Paul, Minn), whose pivot is located in the left atrial portion of the

housing and whose leaflets open within the housing profile, has been believed to be a most suitable valve for chordal-preserving mitral valve replacement. However, several cases in which the preserved subvalvular apparatus were entrapped have been reported.³ The Carbomedics Standard mitral valve (Sulzer Carbomedics, Inc, Austin, Tex), which has been reported to cause few instances of thrombus or pannus formation,⁴ is designed so that the leaflets open beyond the housing profile, which might cause entrapment of retained subvalvular apparatus. With regard to stented bioprosthetic valves, a high-profile valve could cause left ventricular outflow obstruction in the subvalvular apparatus preserving mitral valve surgery as previously reported⁵ (Figure 1).

The On-X mitral valve is designed to prevent pannus ingrowth by high-profile inlet flare, although it is not so high as stented bioprostheses. Our experience showed the feasibility of chordal-preserving mitral valve replacement consisting of various techniques using the On-X valve, although it included a small number of cases. This technique using the On-X valve could bring better long-term outcome in patients undergoing mitral valve replacement.

References

- David TE, Uden DE, Strauss HD. The importance of the mitral apparatus in left ventricular function after correction mitral regurgitation. *Circulation*. 1983;68:76-82.
- Reardon MJ, David TE. Mitral valve replacement with preservation of the subvalvular apparatus. *Curr Opin Cardiol*. 1999;14:104-15.
- Agostini F, Click RL, Mulvagh SL, Abel MD, Dearani JA. Entrapment of subvalvular mitral tissue causing intermittent failure of a St Jude mitral prosthesis. *J Am Soc Echocardiogr*. 2000;13:1121-3.
- Konagai N, Yano H, Makimura S, Nishida K, Iida Y, Sato M, et al. A surgical case for a Carbomedics stuck valve due to thrombotic pannus formation in the mitral position. *Ann Thorac Cardiovasc Surg*. 2005; 11:186-9.
- Jett GK, Jett MD, Bosco P, van Rijk-Swikker GL, Clark RE. Left ventricular outflow tract obstruction following mitral valve replacement: effect of strut height and orientation. *Ann Thorac Surg*. 1986;42: 299-303.

**Feasibility of preservation of subvalvular apparatus in mitral valve replacement
with the On-X mechanical valve**

Hiroshi Tanaka, Teruo Yamshita, Kenji Okada, Keitaro Nakagiri, Yujiro Kawanishi
and Yutaka Okita

J Thorac Cardiovasc Surg 2006;132:1470-1471

DOI: 10.1016/j.jtcvs.2006.08.030

Continuing Medical Education Activities

Subscribers to the Journal can earn continuing medical education credits via the Web at
http://cme.ctsnetjournals.org/cgi/hierarchy/ctsnetcme_node;JTCS

Subscription Information

This article cites 4 articles, 1 of which you can access for free at:
<http://jtcs.ctsnetjournals.org/cgi/content/full/132/6/1470#BIBL>

Permissions and Licensing

General information about reproducing this article in parts (figures, tables) or in its entirety
can be found online at:

http://www.elsevier.com/wps/find/supportfaq.cws_home/permissionusematerial.

An on-line permission request form, which should be fulfilled within 10 working days of
receipt, is available at:

http://www.elsevier.com/wps/find/obtainpermissionform.cws_home/obtainpermissionform

The Journal of
Thoracic and Cardiovascular Surgery